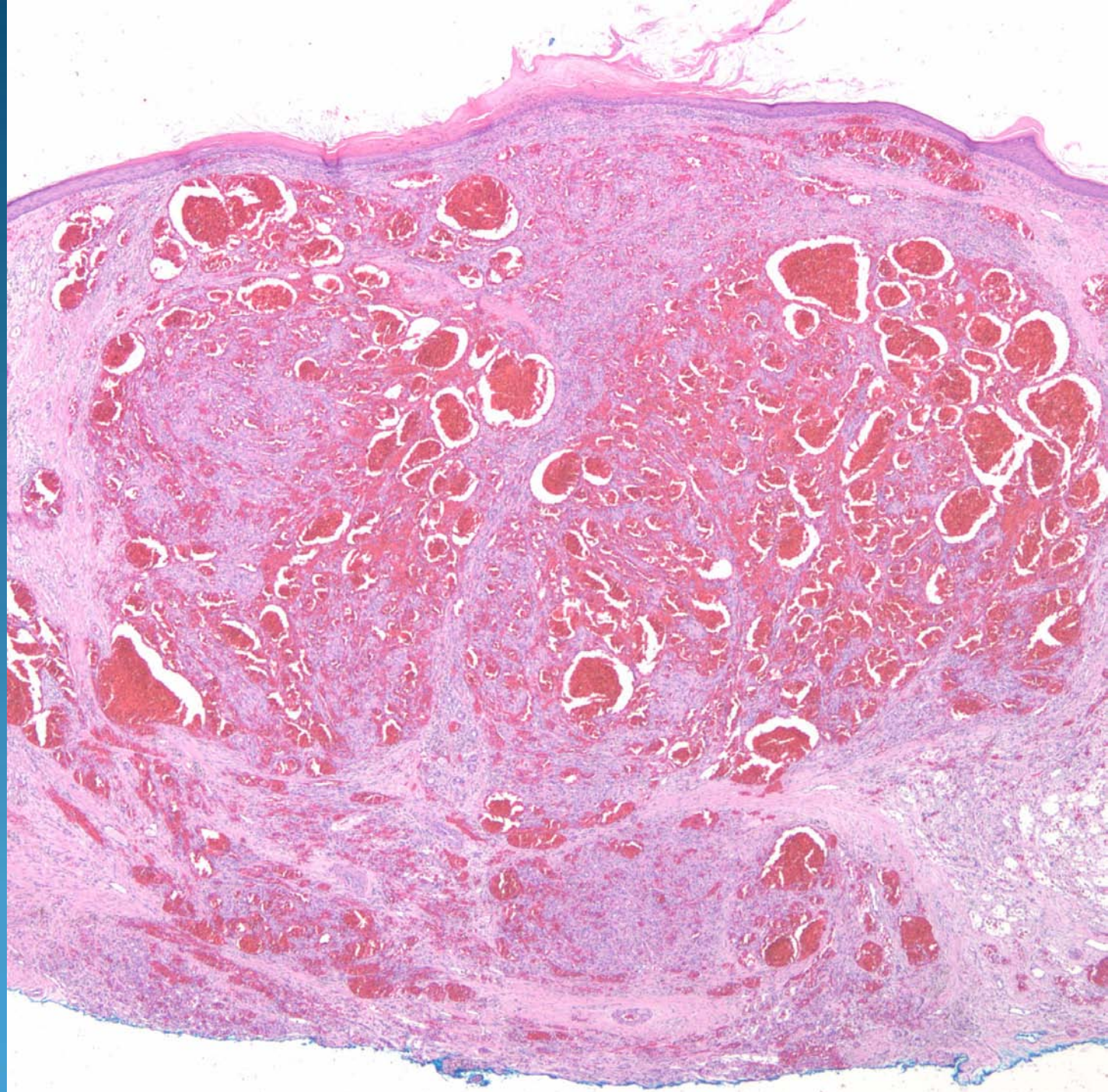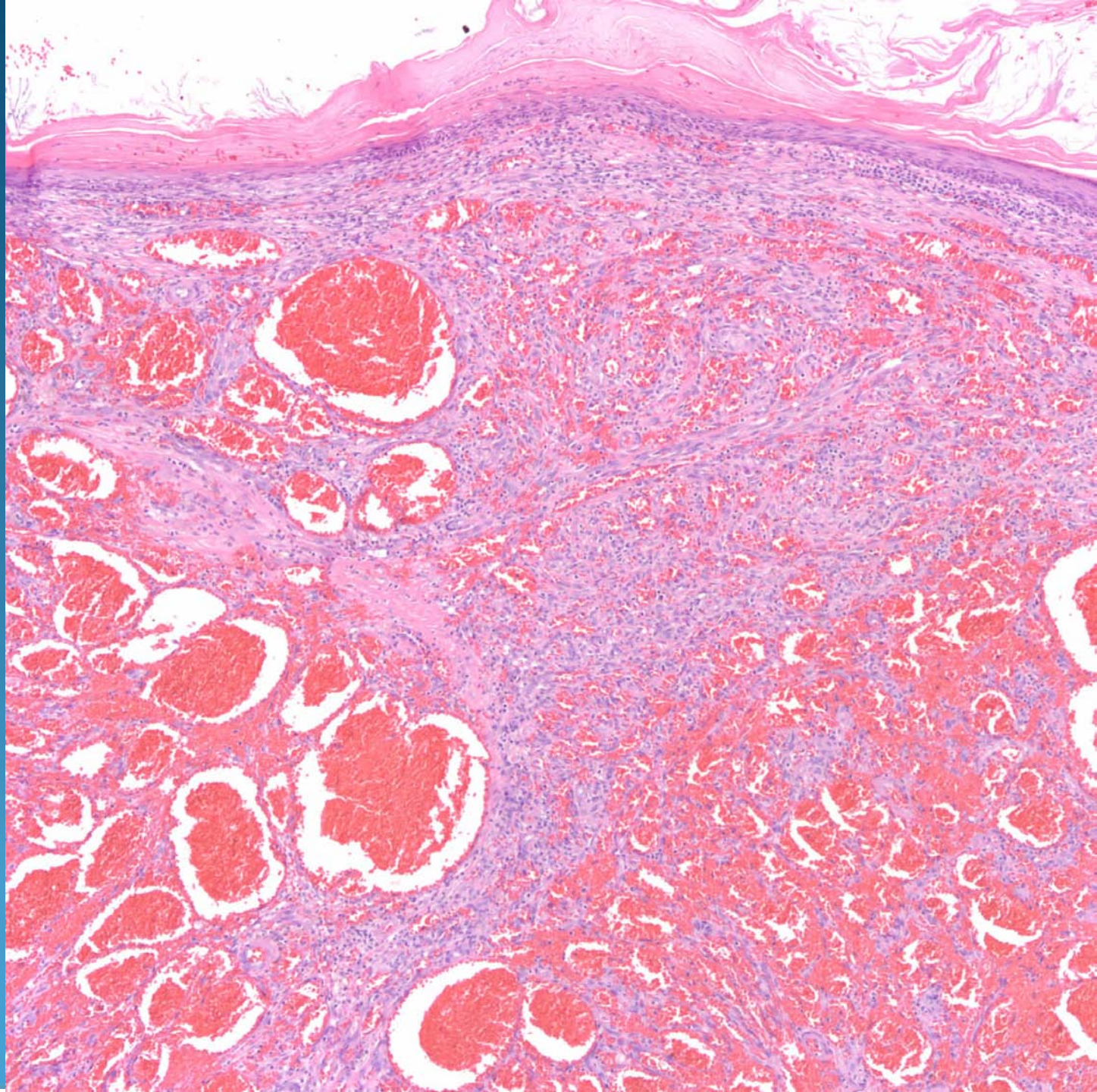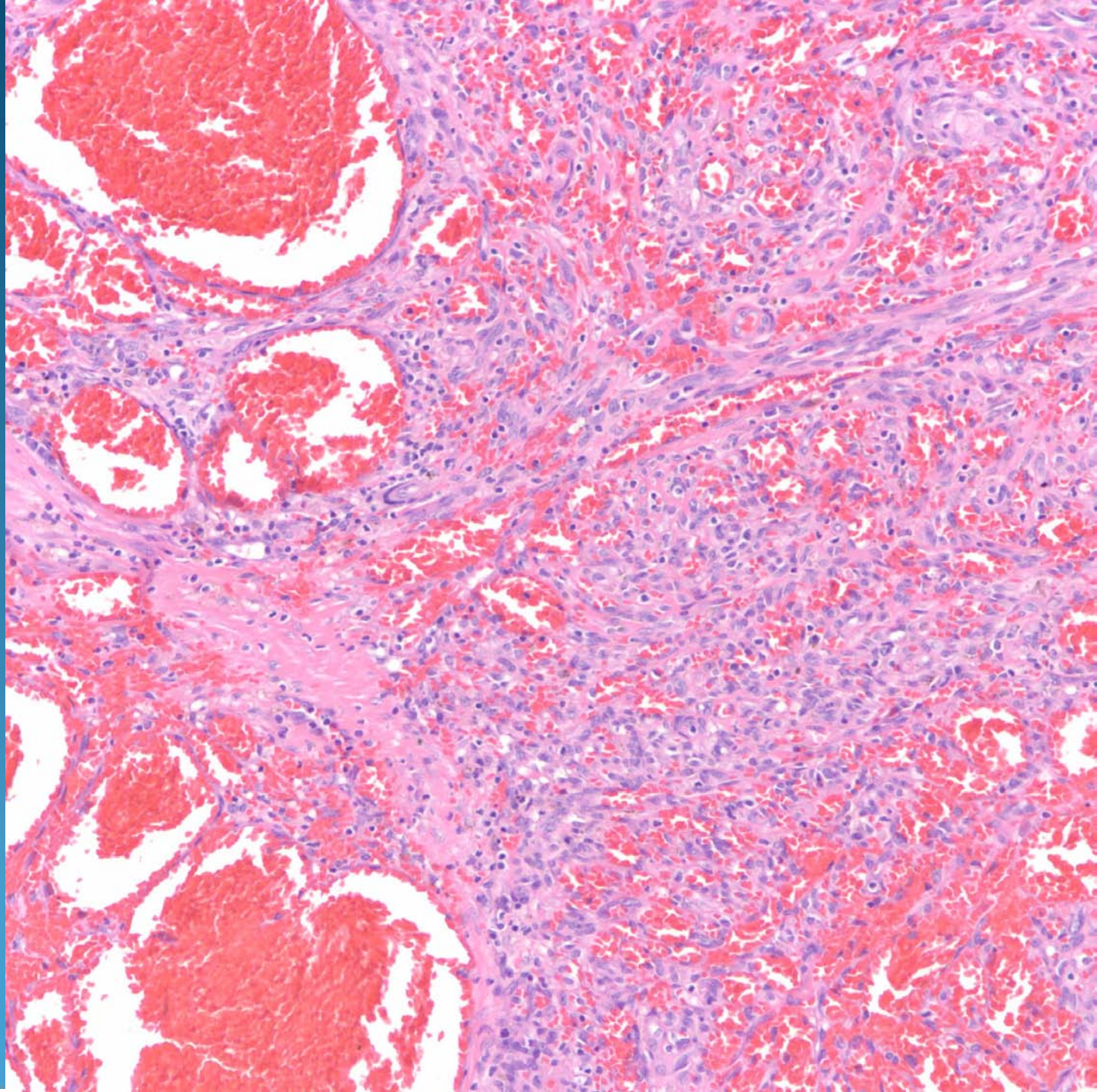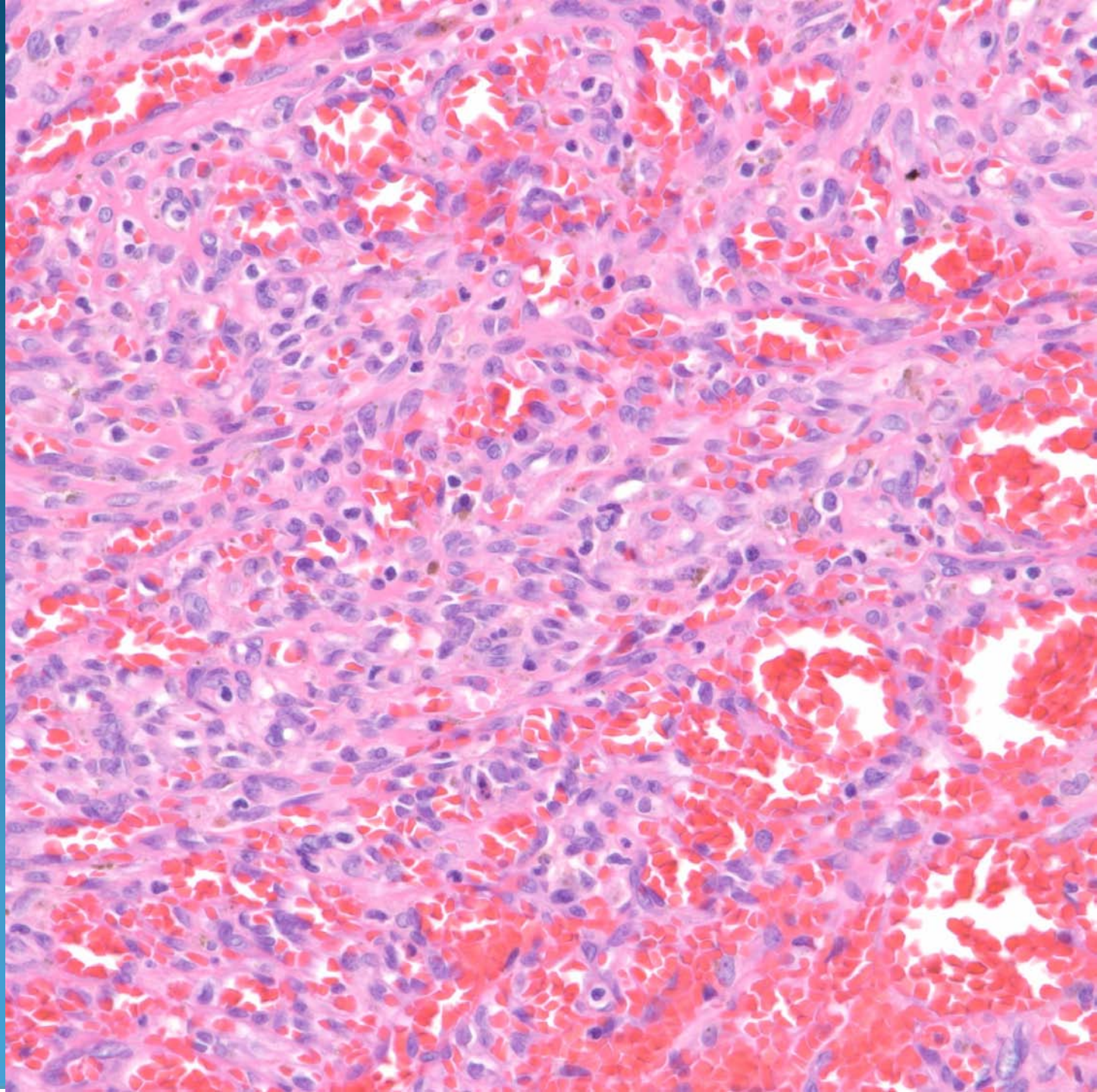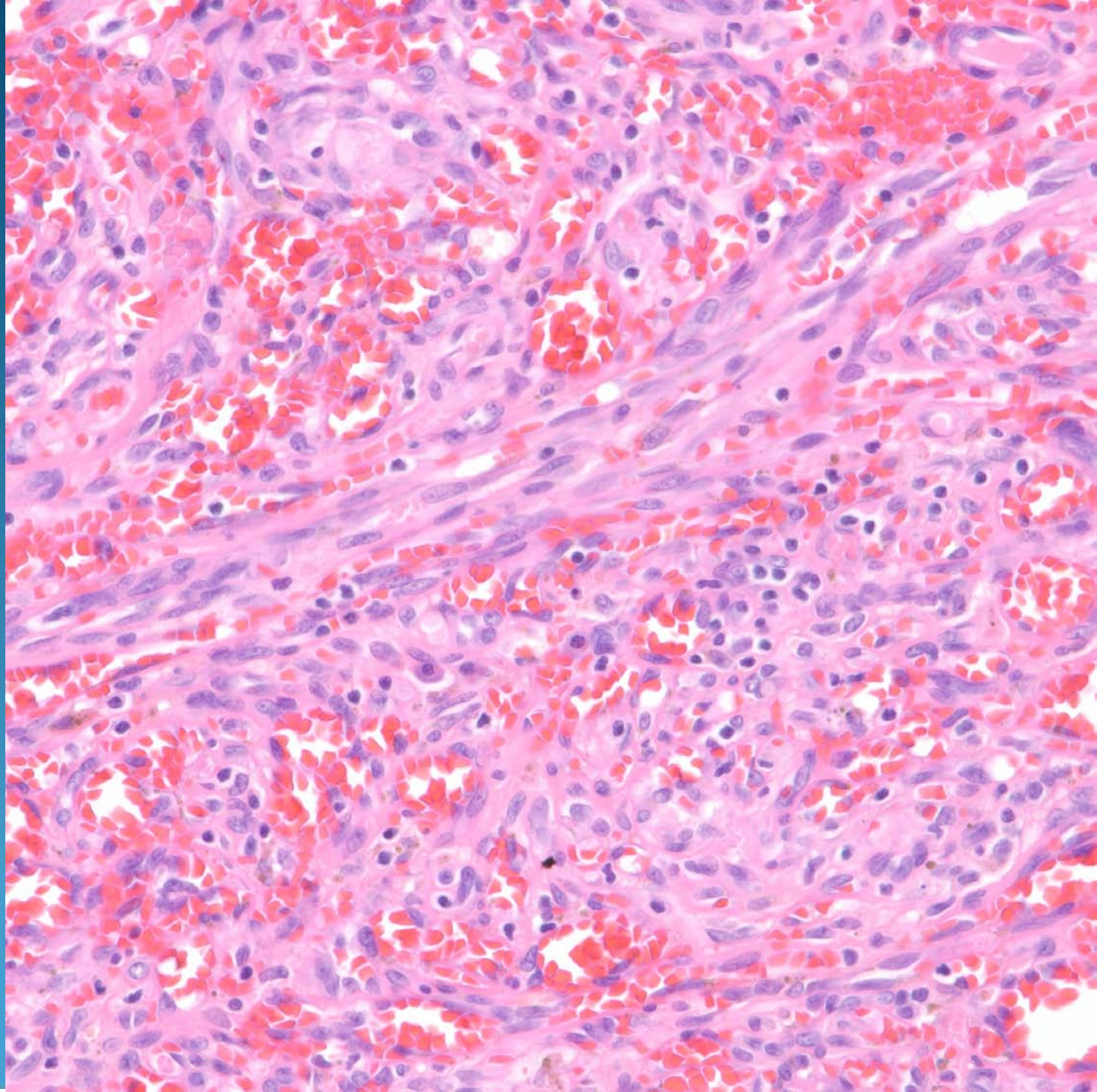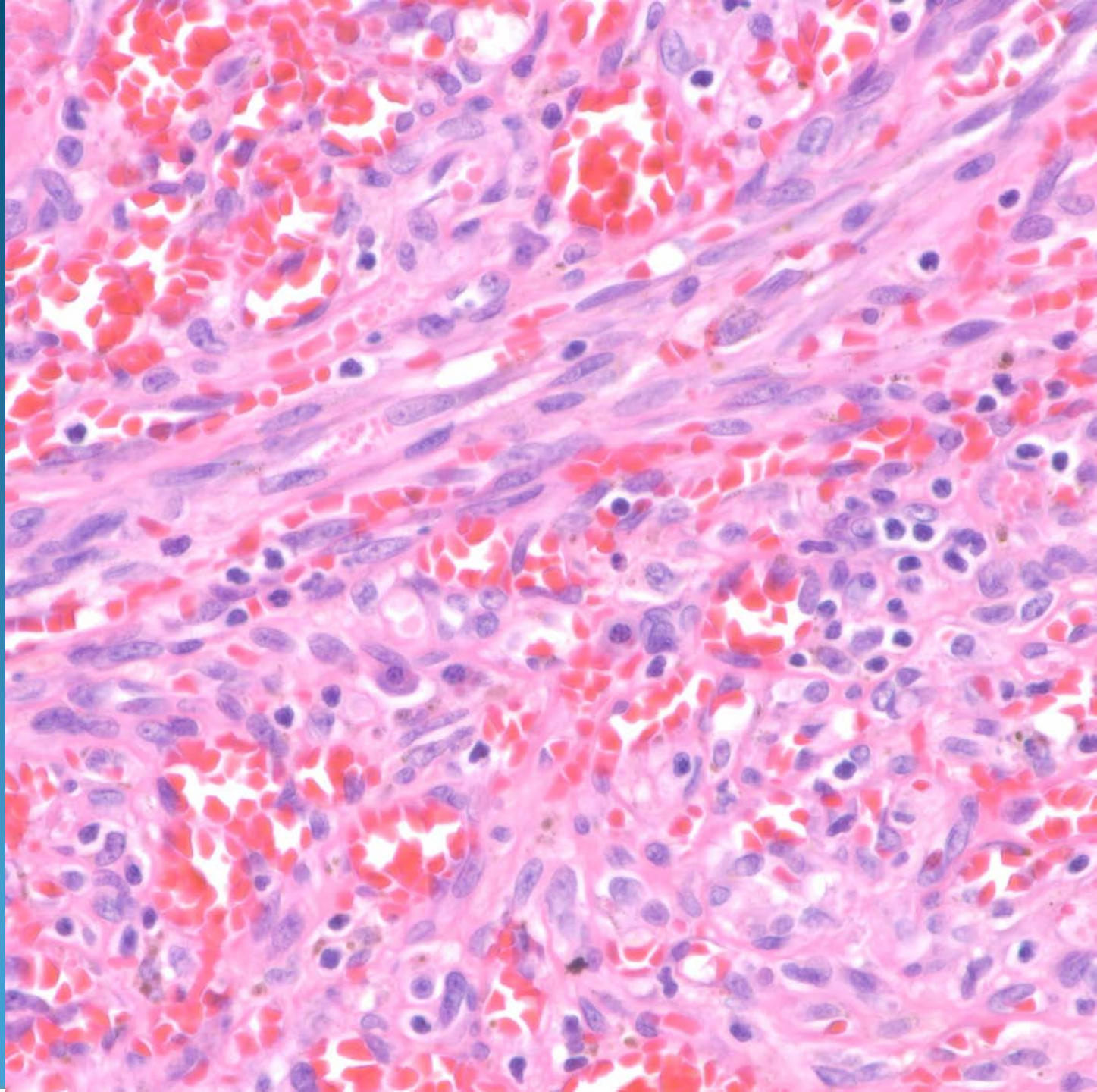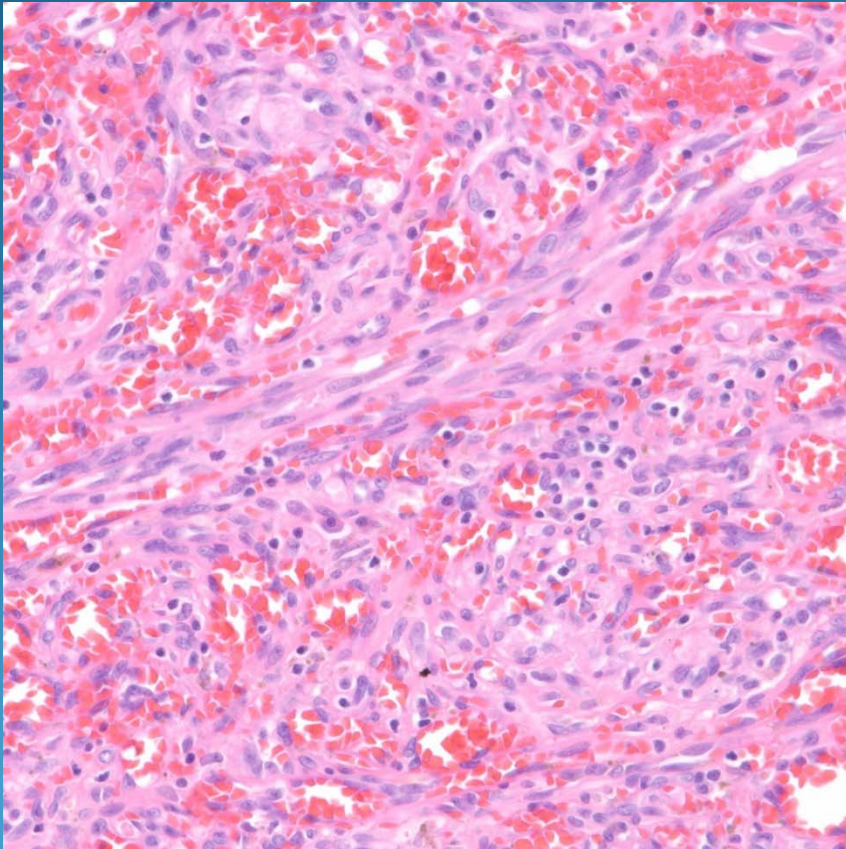


Kaposi's Sarcoma-Tumor Stage

Pearls



- Nodular collection of atypical to frankly malignant spindle cells
- Vascular slits with extravasated red blood cells
- May have ectatic vascular spaces filled with red blood cells
- Scattered plasma cells
- Confirm with CD31 and HHV-8